THE EVOLUTION OF BREAST SCREENING

Since the 1960s, mammography has been the gold standard for breast cancer screening. Later, new imaging techniques, such as the breast ultrasound and MRI, further improved breast cancer detection as they enable closer examination of uncertain findings in a mammogram. Today, these and newly emerging technologies are used as complementary screening tools, especially for high-risk patients, as this dramatically improves breast cancer diagnosis accuracy.

1960s

Mammography gains acceptance as a screening tool for breast cancer.

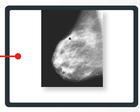

1980s

A new imaging technique, **digital breast ultrasound**, is adopted for diagnosis of subtle findings in a mammogram.

1990s

Just like the ultrasound, the adoption of **breast MRI** leads to better characterization of questionable lesions in mammograms.

2000

The FDA approves the first digital mammography system. Mammography film is gradually being replaced by **digital mammography images**.

Digital mammography requires high-resolution displays to show images with filmlike precision. This kind of resolution can only be obtained with **monochromatic (grayscale) monitors**.

2009

A new screening method called **digital breast tomosynthesis** generates 3D images of the breast and dramatically improves visibility of breast cancers.

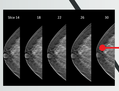

Barco's Mammo Tomosynthesis 5MP

2011

The **FDA** approves the first monitor cleared for viewing digital breast tomosynthesis.

Mammogram | Breast ultrasound | Breast MRI | DBT

The use of breast MRI, breast ultrasound, and 3D mammography as complementary screening tools (and not only for diagnosis) proves to increase breast cancer detection, especially in women at high risk (e.g. dense breasts, family history...). In these cases, **multimodality breast cancer screening** becomes standard practice.

2013

However, mammography displays are not fit to view breast ultrasound or MRI. Radiologists need **two separate workstations** to read these studies, which makes it more difficult to make an efficient diagnosis.

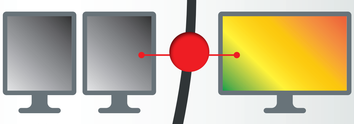

Digital mammography | Breast MRI and ultrasound

2015

Worklist display | Mammography displays | Color PACS displays | Coronis Uniti™

The FDA clears the first display for viewing of multimodality breast images on a single screen. It also features a brightness boost system that has proven to increase visibility of microcalcifications in dense breast tissue by up to 30%*

* Tom Kimpe and Albert Xthona. "Quantification of detection probability of microcalcifications at increased display luminance levels." Breast Imaging. Springer Berlin Heidelberg, 2012. 490-497.

BARCO Visibly yours

www.barco.com/uniti